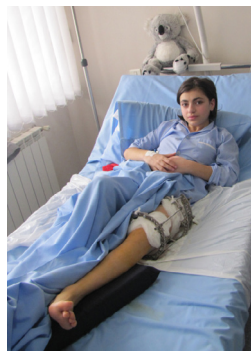

Parsadanyan Anzhela/2002/Charentsavan, Kotayk, Armenia



Operation date: October 20, 2016 (3rd surgery)

Diagnosis: Sequel of osteomyelitis, defect of proximal part of femur, shortening by 5 cm.

Procedure: Left femur subtrochanteric osteotomy, bi-local osteosynthesis by Ilizarov.

Expected results: Elimination of LLD, significant improvement of leg function and gait.

Presumable duration: 4 months

Sponsor(s): Yalkezian Foundation (Canada) Cost: \$ 4700

Avagyan Vardges/1998/village Lernavan, Lori, Armenia

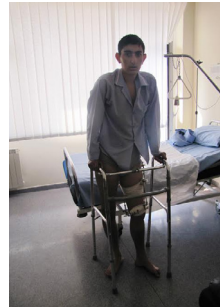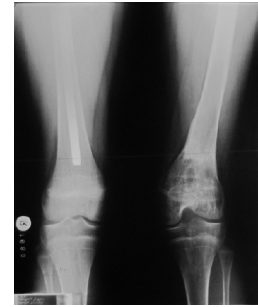
Operation date: October 22, 2016

Diagnosis: Post-traumatic partial growing zone arrest, valgus deformity of knee, shortening of the left femur by 4.5 cm

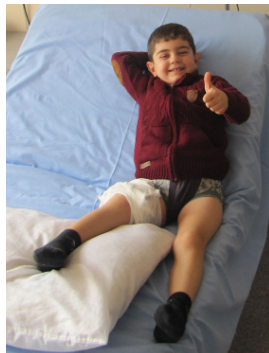Procedure: Osteotomy of the left femur for gradual lengthening and valgus deformity correction, elimination of leg length discrepancy, nail removal from the right femur.

Expected results: Complete restoration of the gait and function of the leg

Presumable duration: 4 months



Sponsor(s): Yalkezian Foundation (Canada) Cost: \$ 6000



Khachatryan Samvel /2010/Shirak, Armenia

Operation date: December 17, 2016 (2nd surgery)

Diagnosis: Chronic hematogenous osteomyelitis, defect of the middle third of the right femur, shortening by 5 cm.

Procedure: osteosynthesis by Ilizarov for lengthening the femur by 5 cm.

Expected results: Elimination of 5cm LLD.

Presumable duration: 6 months

Sponsor(s): Fundraising organised by Mrs. Lilia Chakarian (USA). Cost: \$ 5000

Nersesyan Alina/2009/Ashtarak, Aragatsotn, Armenia

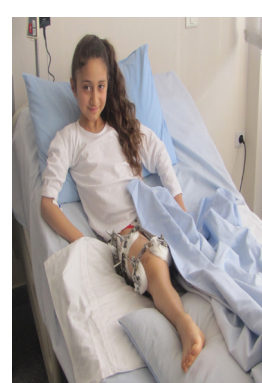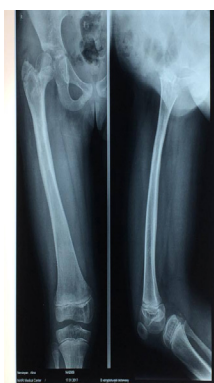Operation date: January 27, 2017

Diagnosis: Congenital abnormality, congenital shortening of right femur by 6 cm

Procedure: Correction of deformity, femur lengthening by Ilizarov method

Expected results: Restoration of the leg length, function and gait

Presumable duration: 6 months



Sponsor(s): Yalkezian Foundation (Canada) Cost: \$ 5500